

CASO CLINICO III: COMPLICANZA LEGATA A POSIZIONAMENTO DI LAMS

CARMELO BARBERA

UOC GASTROENTEROLOGIA ED ENDOSCOPIA DIGESTIVA

ASL TERAMO

EDUCARE

EUS GUIDED DRAINAGES: INDICATIONS

1. **Pancreatic Fluid collections**
   - Pancreatic pseudocyst, necrotic collection, abscess
   - EUS replaces surgery or IR techniques

2. **Gallbladder**
   - Acute Cholecystitis
   - EUS option for non-surgical candidates

3. **Bile Duct**
   - Failed ERCP or malignant duodenal stricture
   - EUS replaces percutaneous drainage

EDUCARE

The stent family has grown!

Stents

- Double pigtails (7, 8,5 & 10Fr)





- Metal stents *(Boston, Taewoong, NitiS)*









EDUCARE

THE AXIOS STENT



Lumen Apposing SEMS

EDUCARE

INTERVENTIONAL EUS: THE HOT AXIOS REVOLUTION

- Before Hot Axios: EUS to access, then fluoroscopic procedure made with an echoendoscope
- After Hot Axios: Interventional EUS-guided procedures done under EUS guidance with fluoroscopy as a back up or help or **FLUOROLESS EUS**

EDUCARE

Boston Scientific Confidential.
For Internal Use Only. Do Not Copy, Display or Distribute Externally

MULTICENTER STUDIES USING SEMS FOR PFCS

Author, yr	No. Pts.	Technical success	Clinical success	Complications
Walter, 2015^	61 (75% WOPN)	98.4%	85%	stent migration (3) o dislodgement (3); infection (4); perforation (1) Total: 18%
Chandran, 2015*	47 (>50%, PC)	98.1%	76.6%	Early (18.6%): stent migration (5), infection (4), bleeding (1) Late (26%): stent migration (6) or occlusion (4), tissue overgrowth/ingrowth (3), bleeding (2)
Rinninella, 2015°	93 (80% complex PFCs)	98.9%	92.5%	massive bleeding (1) perforation (1); pneumoperitoneum (1), infection (1), stent dislodgement (1) Total: 5.1%

^ AXIOS stent, * NAGI stent, ° Hot-AXIOS device

EDUCARE

LAMS-ENDOSCOPIST: A ROYAL WEDDING?



EDUCARE

Happy Ending

CLINICAL CASE

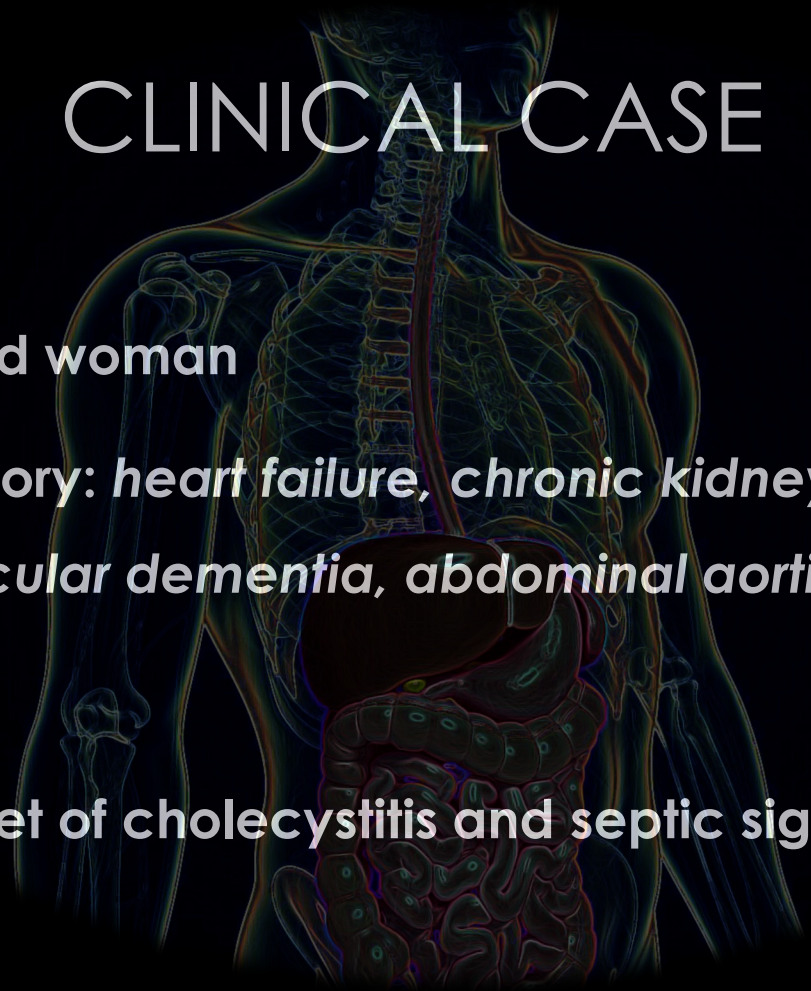

- **93 Years-old woman**
- **Clinical history: *heart failure, chronic kidney disease (stage III), COPD, vascular dementia, abdominal aortic aneurism…***
- **A.S.A. 4**
- **Recent onset of cholecystitis and septic signs**

EDUCARE

Happy Ending

CT SCAN ON ADMISSION…



EDUCARE

Happy Ending

Than, EUS-guided lumen apposing metal stent was deployed…

Happy Ending

HOT AXIOS SYSTEM



EDUCARE

Happy Ending

CT SCAN AT DISCHARGE



EDUCARE

Happy Ending

CLINICAL CASE

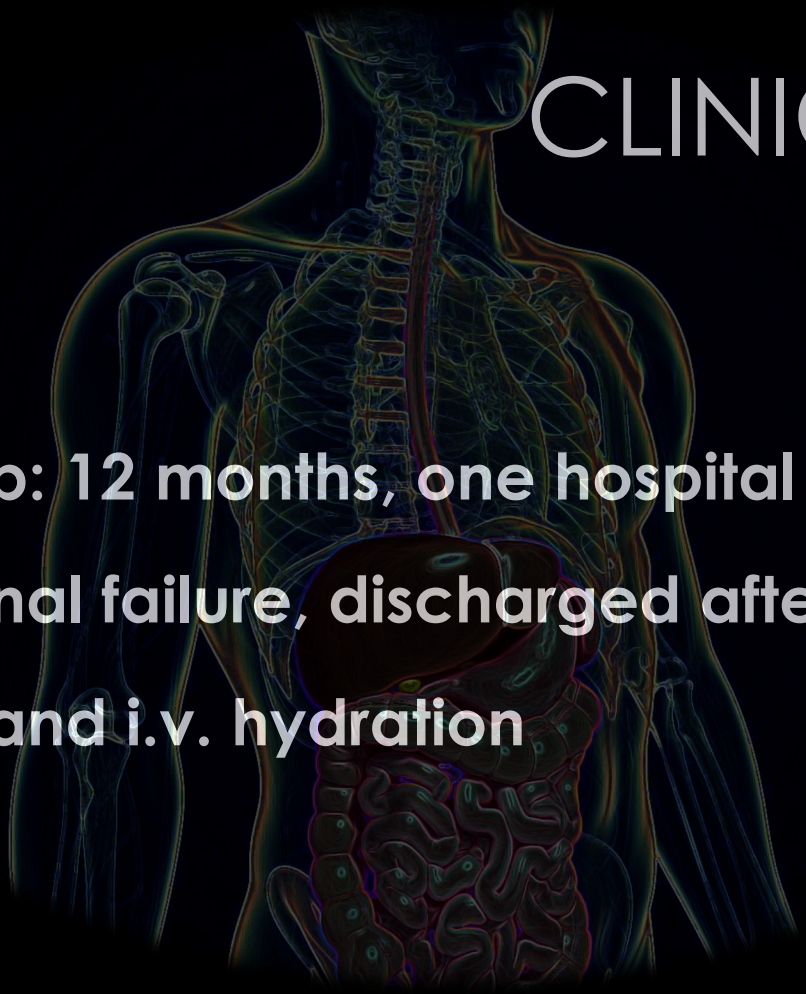

- **Follow-up: 12 months, one hospital admission for acute renal failure, discharged after antibiotic therapy and i.v. hydration**

EDUCARE

EUS-GUIDED GALLBLADDER DRAINAGE

REVIEW ARTICLE

Annals of Gastroenterology (2016) **29**, 162-167

Endoscopic ultrasound-guided placement of the lumen-apposing self-expandable metallic stent for gallbladder drainage: a promising technique

Rashmee Patil[a], Mel A. Ona[b], Charilaos Papafragkakis[c], Sury Anand[b], Sushil Duddempudi[b]

Abstract

Acute cholecystitis and other clinical problems requiring gallbladder removal or drainage have conventionally been treated with surgery, endoscopic retrograde cholangiopancreatography or percutaneous transhepatic drainage of the gallbladder and/or extrahepatic bile duct. Patients unable to undergo these procedures due to functional status or anatomical anomalies are candidates for endoscopic ultrasound (EUS)-guided gallbladder drainage with stent placement. The aim of this review was to evaluate the technical feasibility and efficacy of EUS-guided placement of the recently developed lumen-apposing self-expandable metallic stent (LASEMS). A literature review was performed to identify the studies describing this technique. In this review article we have summarized case series or reports describing EUS-guided LASEMS placement. The indications, techniques, limitations and complications reported are discussed. A total of 78 patients were included across all studies described thus far in the literature. Studies have reported near 100% technical and clinical success rates in selected cases. No major complications were reported. EUS-guided gallbladder drainage and LASEMS placement can be a safe and effective alternative approach in the management of selected patients.

Keywords Endoscopic ultrasound, gallbladder drainage, lumen-apposing stent, AXIOS

Ann Gastroenterol 2016; 29 (2): 162-167

EDUCARE

Table 2 Summary of reports describing endoscopic ultrasound-guided gallbladder drainage with lumen-apposing self-expandable metallic stent (LASEMS)

Study, location	Clinical problem	Stent name	Stent size (mm) Diameter, length	Approach	Puncture needle	Tract dilator	Early complications	Clinical success rate (%)	Technical success rate (%)
Law *et al* (2015) Michigan, USA [21]	Acute cholecystitis	AXIOS	D=10 vs. 15	T =7	19G	4-6 mm dilating balloon	None	100	100
Walter *et al* (2015) The Netherlands [22]	Acute cholecystitis	AXIOS	D=10 vs. 15	NM	19G	NM	Recurrent cholecystitis due to LASEMS occlusion (2)	96	90
Ge *et al* (2015) China [20]	Symptomatic cholelithiasis	Micro-Tech, Nanjing Co.	D=10 L=35	TG	19G	4 mm biliary balloon dilator	None	100	100
Irani *et al* (2015) N. Carolina, USA [16]	Calculous cholecystitis (7) Acalculous cholecystitis(4) Biliary obstruction (2) Gallbladder hydrops (1) Symptomatic cholelithiasis (1)	AXIOS	D= 10 vs. 15 L=10	TD=14 TG=1	19G	4 mm biliary balloon dilator	Post-procedure fever (1)	100	93
Tharian *et al* (2015) Florida, USA [17]	Gallbladder adenocarcinoma, palliative drainage	AXIOS	NM	TD	19G	4 mm biliary balloon dilator	None	100	100
Itoi *et al* (2014) Japan [15]	Acalculous cholecystitis	AXIOS	D=6 L=8	TD	19G	NM	None	100	100
Moon *et al* (2014) Japan [19]	Acute cholecystitis	AXIOS	D=8,10,15 L=10	TG	19G	4 mm biliary balloon dilator	None	100	100
Higuera *et al* (2013) Spain [13]	Acute cholecystitis	AXIOS	D=10 vs. 15 L=6-10	TG=12 TD=1	19G	4 mm biliary balloon dilator	Hematochezia (1) Right hypochondrium pain (1)	100	84.61
Itoi *et al* (2013) Japan [18]	Malignant biliary obstruction	AXIOS	D=10 L=10	TG	19G	4 mm biliary balloon dilator	None	100	100
Monkemuller *et al* (2013) Germany [12]	Acute cholecystitis	AXIOS	D=10	TG	19G	No dilator used	None	100	100
Itoi *et al* (2012) Japan [11]	Pancreatic cancer (3) Bile duct cancer (2) Cholelithiasis (1)	AXIOS	D=10 L=6	TD=4 TG=1	19G	4 mm biliary balloon dilator	None	100	100

D, diameter; L, length; TD, transduodenal; TG, transgastric; G, gauge; NM, no mention

EDUCARE

EUS-guided Versus Percutaneous Gallbladder Drainage: Isn't It Time to Convert?

Journal of clinical gastroenterology. ():, Dec 2016

Amy Tyberg; Monica Saumoy; Enrique V Sequeiros; Marc Giovannini; Everson Artifon; Anthony Teoh; Jose Nieto; Amit P Desai; Nikhil A Kumta; Monica Gaidhane; Reem Z Sharaiha; Michel Kahaleh show less

BACKGROUND AND AIMS

Endoscopic ultrasound-guided drainage (EUS-GLB) is a minimally invasive option for patients with cholecystitis who are poor surgical candidates. Compared with percutaneous drainage (PC-GLB), earlier studies have demonstrated similar efficacy with improved quality of life. We present a multicenter, international experience comparing PC-GLB and EUS-GLB in nonsurgical patients with cholecystitis.

METHODS

All patients who underwent either PC-GLB drainage or EUS-GLB drainage from 7 centers between January 2010 and December 2015 were included. Technical success was defined as successful placement of a catheter or stent into the gallbladder. Clinical success was defined as resolution of clinical symptoms after intervention. Adverse events, length of stay, and the need for repeat interventions and/or hospitalizations were recorded for all patients.

RESULTS

A total of 155 patients were included (mean age 74±14.24 y; range, 31 to 96; 56% male). Forty-two patients underwent EUS-GLB and 113 patients underwent PC-GLB. Technical success was achieved in 40 patients (95%) in the EUS-GLB group and 112 patients (99%) in the PC-GLB group (P=0.179). Clinical success was achieved in 40 patients (95%) in the EUS-GLB group and 97 patients (86%) in the PC-GLB group (P=0.157). There was no difference in hospital readmission rates between the 2 groups (14% vs. 24%; P=0.194). However, there was significantly higher number of patients requiring repeat interventions in the PC-GLB group (n=28, 24%) compared with the EUS-GLB group (n=4, 10%) (P=0.037). There was no difference in adverse events between the 2 groups.

CONCLUSIONS

EUS-GLB is safe and efficacious, with comparable technical and clinical success rates and no difference in adverse events. In addition, EUS-GLB offers a potential cost-saving benefit and morbidity benefit by demonstrating a decreased number of repeat interventions.

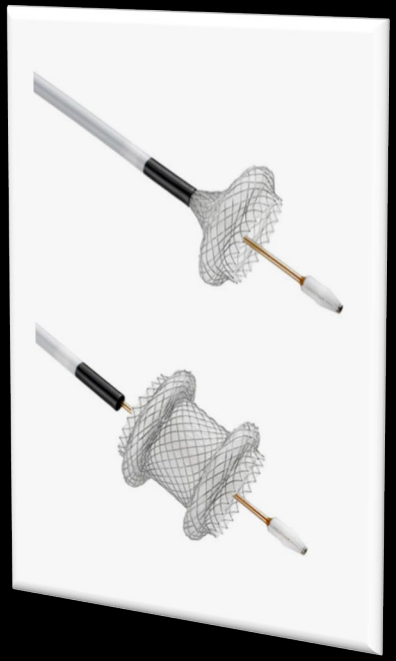

EDUCARE

No happy Ending

CLINICAL CASE

A 88-year-old male with jaundice (total bilirubin > 20 mg/dl), COPD, dementia, heart failure.

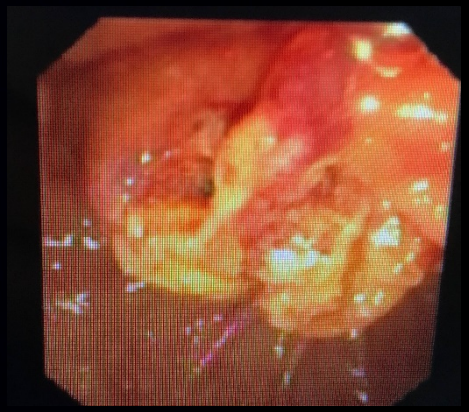

Previous EUS showed T3N1Mx ampullary adk

ERCP failure

EUS-guided drainage using lumen-apposing metal stent

EDUCARE

EUS-GUIDED BILIARY DRAINAGE

Intrahepatic

Extrahepatic

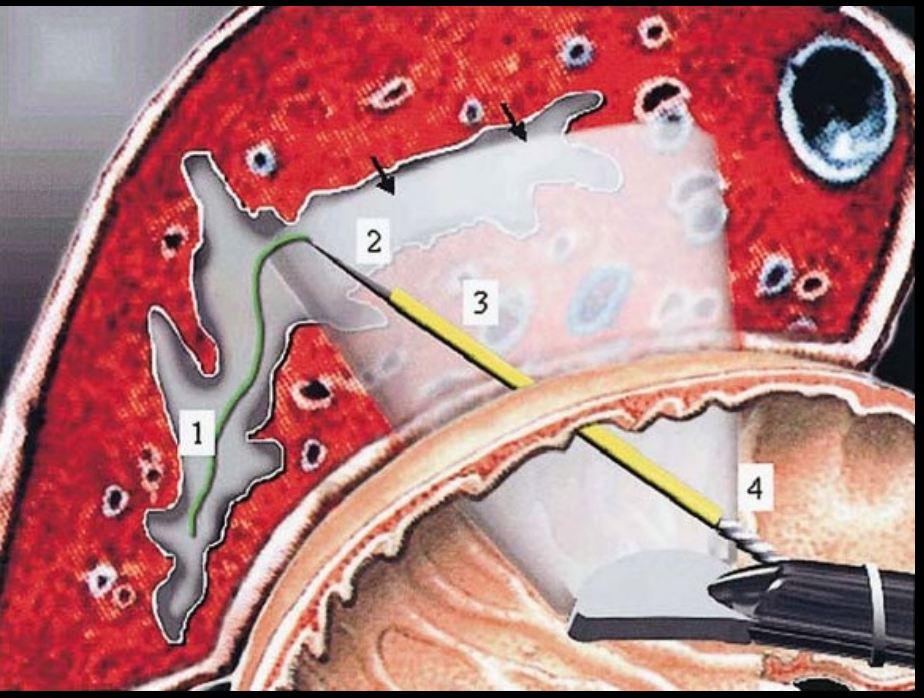



Hepaticogastrostomy

Choledocoduodenostomy

EDUCARE

No Happy Ending

Than, EUS-guided choledocoduodenostomy by lumen apposing metal stent was performed…

NO HAPPY ENDING



EDUCARE

NO HAPPY ENDING



EDUCARE

NO HAPPY ENDING

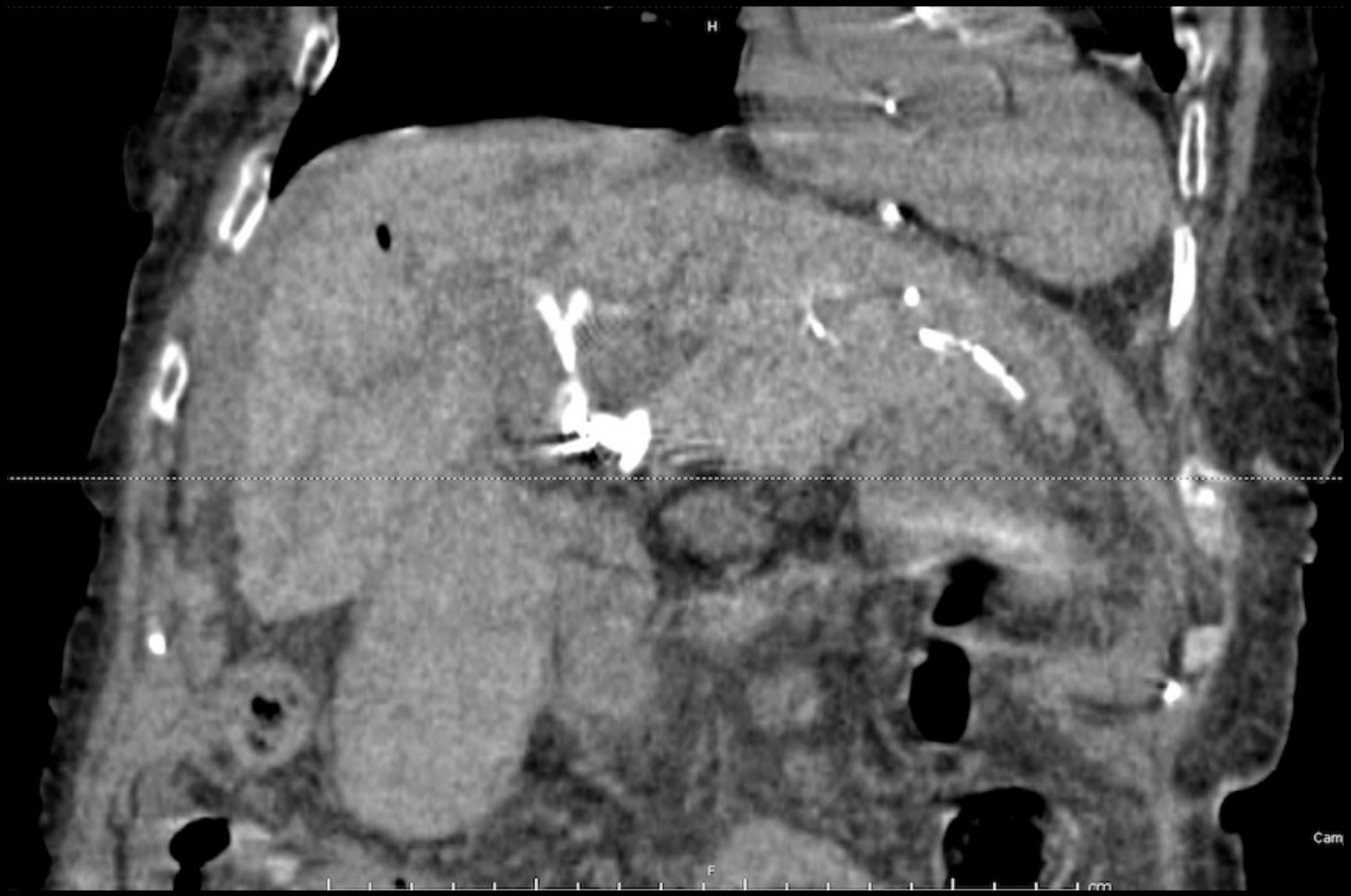

EDUCARE

NO HAPPY ENDING



EDUCARE

EUS-BILIARY DRAINAGE: AXIOS AND HOT AXIOS

Retrospective study on 57 patients with CBD obstruction after failed ERCP in 7 EU Centers

- Duodenal stenosis 53%, Ascites 28%
- Axios/Hot Axios: 27/30
- Technical success 96.9%
- Clinical success 93.7%
- 4 major complications: bleeding requiring embolization, duodenal perforation due to partial stent release, transient cholangitis, stent migration

Kunda R, et al. Surg Endosc 2015:.

EDUCARE

Boston Scientific Confidential.
For Internal Use Only. Do Not Copy, Display or Distribute Externally

NO HAPPY ENDING

What was wrong?

- *Position?*
- *Caliber?*
- *Technique?*
- *Endoscopist?*

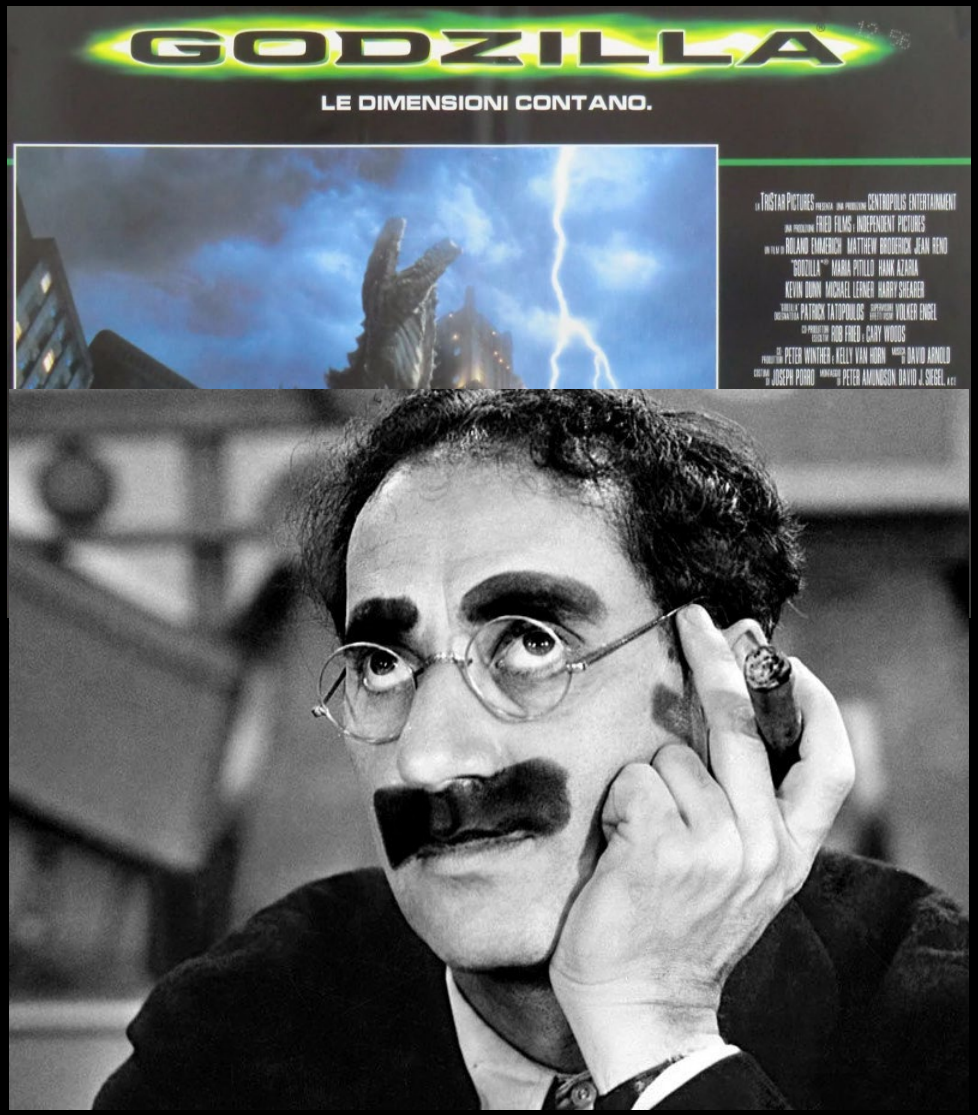

EDUCARE

TO BE HAPPY, BE CAREFUL AND CHOOSE WELL





EDUCARE

THANK YOU SO MUCH



EDUCARE